

# **FIXED PROSTHODONTICS OPERATIVE DENTISTRY**

---

**DAVID E. BEAUDREQU, SAMUEL E. GUYER,  
WILLIAM LEFKOWITZ, Section editors**

## **Articulator Selection for Restorative Dentistry**

**Sumiya Hobo, D.D.S., M.D.S.,\* Herbert T. Shinningburg, Jr., D.D.S.,\*\* and  
Lowell D. Whitsett, D.D.S.\*\*\***  
*Tokyo, Japan, and Oklahoma City, Okla.*

The articulator selected, and even more importantly, the skill and care with which it is used, have a direct bearing on the success of fixed or removable restorations. Were the dentist's only concern the relationship of the opposing teeth at the point of maximum intercuspation, both the design and the use of an articulator would be greatly simplified. Since the position of intercuspation is static, the articulator need act only as a rigid hinge—little more than a handle for the cast.

The mandible, however, does not act as a simple hinge. Rather, it is capable of rotation about axes in three planes. The occlusal morphology of any restoration for the mouth must accommodate the free passage of the opposing teeth without interfering with the movement of the mandible.

Because of their potential for producing disease, occlusal interferences must not be incorporated into restorations placed by the dentist. One method of preventing this problem has been to use fully adjustable articulators which duplicate the mandibular movements with a high degree of precision. Treatments using these articulators are time-consuming and demand great skill by the dentist and the technician. As a result, the cost of such treatment does not make it feasible for most smaller routine treatment plans.

Most single crowns and simple fixed partial dentures are fabricated on small hinge articulators that have limited ability to duplicate mandibular movement or none at all. While many of the inaccuracies produced by this type of instrument may be corrected in the mouth using valuable chair time, the end result is an occlusion that is less than optimal. Unfortunately, many of these inaccuracies are not recognized and are allowed to remain in the mouth as occlusal interferences which frequently produce symptoms of occlusal disease.

---

\* Professor and Chairman, Department of Occlusion, Tohoku Dental College.

\*\* Associate Professor and Chairman, Department of Fixed Prosthodontics, University of Oklahoma College of Dentistry.

\*\*\* Associate Professor and Chairman, Department of Occlusion, University of Oklahoma College of Dentistry.

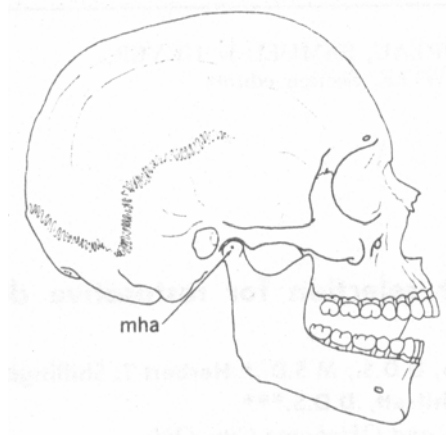


Fig. 1. When the mandible closes around its hinge axis (mha), the cusp tip of the mandibular first premolar moves along an arc.

### **OCCLUSAL INTERFERENCES**

The four types of occlusal interferences are (1) centric occlusal interferences, (2) working occlusal interferences, (3) nonworking occlusal interferences, and (4) protrusive occlusal interferences.

The centric occlusal interference is an occlusal prematurity which causes the mandible to deflect forward and/or laterally from the optimum mandibular position that occurs with the condyles firmly seated in the most superior position in the glenoid fossa.<sup>1</sup>

Centric occlusal interferences may produce clenching and/or bruxism with their associated symptoms of muscle pain and fatigue.<sup>2</sup>

A working occlusal interference occurs between maxillary and mandibular teeth during a lateral mandibular movement on the side corresponding to the direction in which the mandible has moved.

A nonworking occlusal interference is a deflective occlusal contact occurring between maxillary and mandibular teeth during a lateral mandibular movement on the side opposite the direction in which the mandible has moved. The destructive nature of the nonworking occlusal interference has been widely reported.<sup>3-6</sup> Its potential for damaging the masticatory apparatus has been attributed to changes which occur in mandibular leverage, the placement of forces outside the long axes of the teeth, and disruption of normal muscle function.<sup>7</sup>

The protrusive occlusal interference is a deflective contact between the mesial aspects of mandibular posterior teeth and the distal aspects of maxillary posterior teeth during a protrusive mandibular movement. Protrusive occlusal interferences prevent the posterior teeth from being disoccluded by the incisors.

### **ERRORS IN OCCLUSAL RESTORATIONS**

No existing articulator will reproduce all mandibular movements exactly, nor is this its primary objective. The goal is to make a restoration with an occlusal morphology

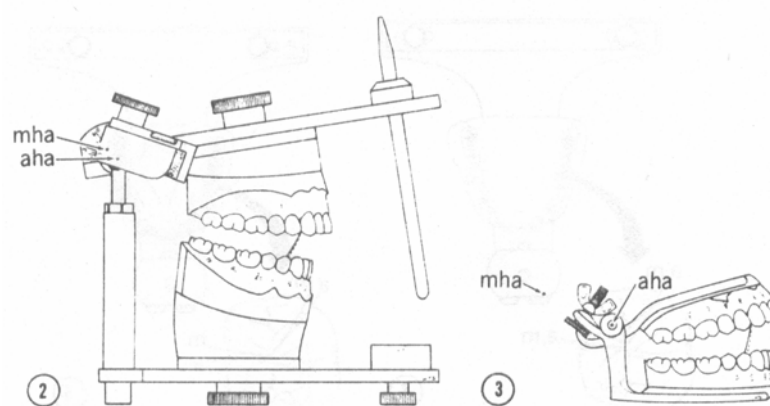


Fig. 2. As a result of the discrepancy between the hinge axis of this semiadjustable articulator (aha) and the mandibular hinge axis (mha), there is a slight discrepancy between the arc of closure of the articulator (broken line) and the arc of closure of the mandible (solid line).  
Fig. 3. The large discrepancy between the hinge axis of the small hinge articulator (aha) and the mandibular hinge axis (mha) produces a larger discrepancy between the arc of closure of the articulator (broken line) and the arc of closure of the mandible (solid line).

compatible with the movements of the mandible. The errors which can be produced range from negligible on the large fully adjustable articulator to ones of considerable magnitude on the small hinge instruments. The errors can be broadly classified in two categories: positive and negative.

A positive error on the occlusal surface is one which occurs when the articulator *undercompensates* for the mandibular movement, resulting in a positive feature existing on the occlusal surface where that feature should be smaller or nonexistent; e.g., a cusp tip or ridge that is too high or one that is in the path of an opposing ridge or tip during a mandibular excursion.

A negative error occurs when the articulator *overcompensates* for a mandibular movement. This results in a negative feature, such as a fossa or groove that is wider than ideal, or conversely in a positive feature, such as a ridge or cusp that is somewhat narrower than ideal. Such posterior teeth are allowed to disocclude more freely when the mandible moves.

Disocclusion of posterior teeth has been described as one of the goals of occlusal treatment.<sup>8 9 10 11</sup> If contacts are maintained in centric relation, negative errors can be acceptable, since the result is a *slightly* flatter occlusal surface. Use has been made of controlled overcompensation (i.e., negative error) in occlusal treatment.<sup>12</sup> However, this should not be carried to the extreme of producing a nearly flat, amorphous occlusal surface. The need for well-defined cusps has been described,<sup>13</sup> and the role of well-defined morphology has been tied to the stabilization and efficiency of the teeth.<sup>10</sup> Care must be taken, therefore, to avoid excessive negative error, since it can result in a loss of occlusal efficiency.  
RADIUS OF MOVEMENT AND OCCLUSAL MORPHOLOGY

When the jaw close, a cusp tip of a mandibular tooth travels along an arc in a sagittal plane, with the center of rotation at the hinge axis (Fig. 1). If the location of the axis of rotation

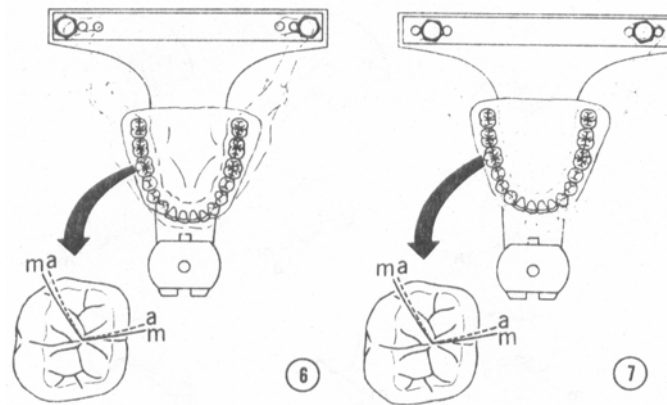


Fig. 4. The path traveled by the mesiolingual cusp of the maxillary right first molar is shown on the occlusal surface of the mandibular right first molar. When the intercondylar distance and tooth-hinge axis distance are accurately reproduced on the articulator, the nonworking (buccal) and working (lingual) paths on the articulated casts coincide with those on the tooth in the patient's mouth. (In Figs. 4 to 8, a purely rotational nontranslating movement of the working-side condyle is presumed.)

Fig. 5. The articulator paths of movement (a) are slightly mesial to the paths in the patient's mouth (m) when the intercondylar distance of the articulator is less than that of the mandible.

in relation to the cusp tip differs from the articulator to the patient, the radius of the arc of movement of the cusp tip may be different or the center of rotation may be displaced, and an error will exist. Differences between that radius of movement on the articulator and that in the patient's mouth can affect the placement of cusps, ridges, and other features of the occlusal surface.

For maximum accuracy, the distance between the hinge axis and the tooth being restored should be transferred from the patient to the articulator by the use of a face-bow. If the casts are mounted so that the articulator closes around a different hinge axis than does the patient's mandible, when the interocclusal record is removed, the teeth will come together in a position on the instrument that is different from that in the mouth. This may occur when no face-bow is used or if only an approximate hinge axis is employed.<sup>14</sup> If a face-bow transfer from a kinematically located hinge axis is not employed, the interocclusal record must be made at *no* increase in the vertical dimension of occlusion.

When an approximate (or arbitrary) hinge axis is used in making the face-bow record, the radius of movement produced on the articulator will reproduce the tooth-axis relationship with a fair degree of accuracy, and the resulting error will be slight (Fig. 2). If the casts were mounted at no increase in the vertical dimension of occlusion, there should be no effect on the occluded casts.

Casts mounted on a small hinge articulator produce an error that is likely to be significant (Fig. 3). During closure in the centric position, the tooth mounted on a small articulator has a much shorter radius of movement. As a result, the tooth travels a somewhat steeper arc of closure on the small instrument than it would in the mouth. If the casts are mounted at an increased

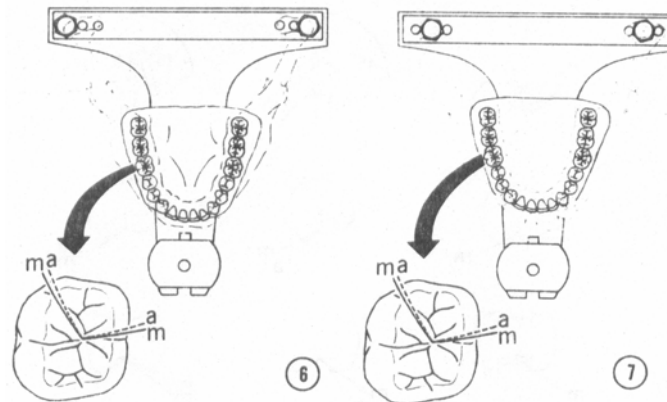


Fig. 6. The paths of movement on the articulator (a) are slightly distal to the paths traced in the mouth (m) when the intercondylar distance of the articulator is greater than that of the mandible.

Fig. 7. The cusp paths traveled on the articulator (a) are distal to those in the mouth (m) when the casts are moved close to the condyles on the articulator.

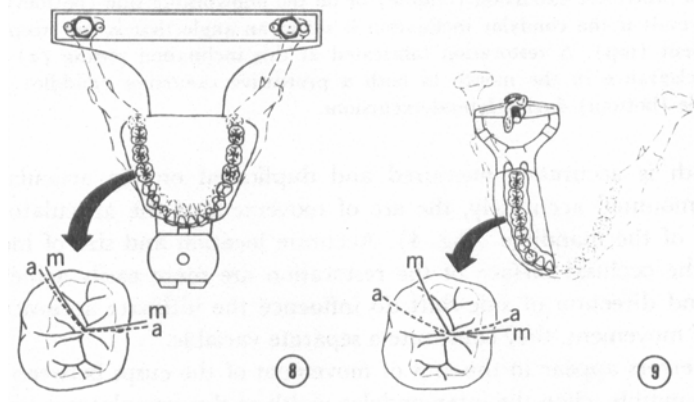


Fig. 8. The cusp paths on the articulator (a) move mesial to those in the mouth (m) when the casts are placed farther from the condyles.

Fig. 9. There is a major discrepancy between the nonworking cusp path on the small hinge articulator (a) and that in the mouth (m).

vertical dimension of occlusion, the casts will occlude in a different intercuspal position on the articulator than in the mouth. If the casts are mounted on a small articulator at no increase in the vertical dimension of occlusion (i.e., at the intercuspal position), a slight positive error on the mesial incline of maxillary teeth and the distal incline of mandibular teeth could result. This might produce a deflective occlusal contact of the nature described by Hodge and Mahan.<sup>15</sup>

The mediolateral location of the centers of rotation (i.e., the intercondylar width) can also change the radius of movement and affect the arcs traveled by the cusps during lateral mandibular excursions in the horizontal plane. If the intercondylar width is accurately measured and

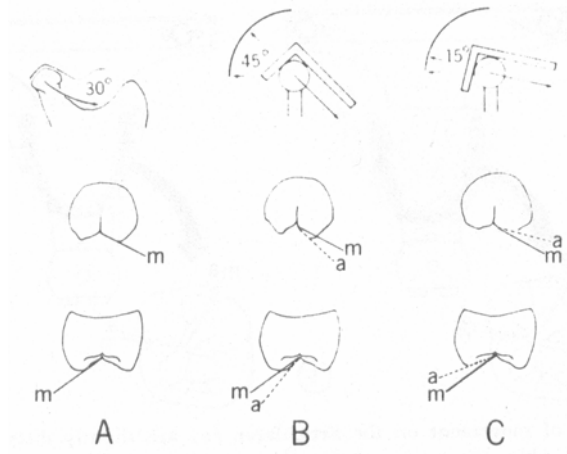


Fig. 10. (A) If the condylar inclination in the patient is 30 degrees (top), the cusp inclines (m) in a protrusive excursion (middle) and on the nonworking side in a lateral excursion (bottom) are in harmony. (B) If the condyle inclination on the articulator is set at a steeper angle than exists in the patient (top), a restoration fabricated to that incline (a) will possess a positive error. When the restoration is placed in the mouth, there may be an occlusal interference in a protrusive excursion (middle) or on the nonworking side (bottom). (C) A negative error will result if the condylar inclination is set at an angle that is less steep than that found in the patient (top). A restoration fabricated at this inclination setting (a) will demonstrate a greater clearance in the mouth in both a protrusive excursion (middle) and on the nonworking side (bottom) during lateral excursions.

duplicated on the articulator and if the casts are mounted accurately, the arc of movement of the articulator will approximate that of the mandible (Fig. 4). Accurate location and size of morphologic features on the occlusal surface of the restoration are more easily achieved. While the amount and direction of side-shift do influence the ultimate accuracy of the reproduction of movement, they constitute a separate variable.

Slight errors appear in the arcs of movement of the cusps between the articulator and the mandible when the intercondylar width of the articulator is less than (Fig. 5) or greater than (Fig. 6) that of the mandible. Errors of similar magnitude occur when the casts on the articulator are moved closer to (Fig. 7) or farther from (Fig. 8) the condyles.

However, when the casts are mounted on a small hinge articulator, the error produced on the nonworking side is of a much greater magnitude (Fig. 9). In this situation, there is an increased likelihood of producing a nonworking occlusal interference in the restoration.

### CONDYLAR INCLINATION AND OCCLUSAL MORPHOLOGY

Condylar inclination affects the angulation of the cusps of the teeth in both protrusive and nonworking movements (Fig. 10, A). A steep condylar inclination allows steeper inclines on the cusps of the teeth, while a less steep inclination demands a flatter occlusal surface with shallower cuspal inclination. If the articulator condylar path is set at a steeper angle than that which exists in the patient (Fig. 10, B, top), the resulting restoration will have cusps that have overly steep

**Table 1.** Matching treatment with articulators

Treatment Use	Articulator	Manufacturer
Single restoration	1. Simplex articulator 2. Laboratory Technical 3. Steele's articulator	Dentsply International, Inc. York, PA Teledyne Dental (Hanau Div.) Buffalo, NY Columbus Dental Mfg. Co. Columbus, OH
Multiple restorations Fixed partial Dentures, and Mimimal occlusal Pathology	1. Mark II articulator 2. ARH articulator 3. H-2 articulator 4. New Occlusomatic Articulator 5. Teledyne articulator 6. Whip-Mix articulator	Denar Corporation, Anaheim, California A B Dentatus, Hagersten, Sweden (available through Almore Mfg. Co. Portland, Oregon Teledyne Dental (Hanau Div. ) Buffalo, NY Shizai International, Inc. Tokyo, Japan (available through U.S. Shizai Corporation Los Angeles, CA) Teledyne Dental (Hanau Div.), Buffalo, NY Whip-Mix Corporation, Louisville, KY
Multiple restorations In opposing quadrants, Full-mouth reconstruc- Tion, and extensive Occlusal pathology	1. Aderer simulator 2. D 5-A articulator 3. Model P 4. Stuart articulator 5. TMJ articulator	J. Aderer, Inc. Long Island City, NY Denar Corporation, Anaheim, CA Panadent Corporation, Colton, CA C.E. Stuart, Ventura, CA TMJ Instrument Company, Inc. Thousand Oaks, CA

inclines. A positive error exists and an occlusal interference may result during a protrusive excursion (Fig. 10, B, middle) or during a nonworking excursion (Fig. 10, B bottom) after the restoration is cemented.

If the articulator inclines are less steep than those of the patient (Fig. 10, C, top), an error will result, but it will be a negative one – a flatter occlusal surface with shallower cusp inclines in both a protrusive excursion (Fig. 10, C, middle) and a nonworking excursion (Fig. 10, C, bottom). Within limits, a negative error is acceptable provided that centric occlusal contacts are maintained. If an error must be made, one which produces greater clearance is preferred.

### **MATCHING THE ARTICULATOR WITH THE TREATMENT**

If the use of a fully adjustable articulator is not feasible for every restoration, how much of a compromise can be made without adversely affecting the restoration? There is no absolute answer. There is no articulator that is “right” for every situation (Table 1).

For most single restorations, a nonadjustable articulator with a fixed condylar path will produce an acceptable result. A large instrument is preferable to minimize errors arising from discrepancies in tooth-hinge axis radius and intercondylar distance. A shallow (20 degrees) fixed condylar inclination is desirable, but not because it closely approximates anatomic averages or represents the inclination found in a large segment of the population. Rather, it is chosen because the error produced will almost always be a negative one: There will be greater tolerance in excursions than is needed. While a negative error is not ideal, it offers an acceptable compromise.

Inaccuracies and errors will occur with this type of instrument. However, they will be much smaller than those produced by the small hinge instrument. If the dentist knows where to look for these errors, they can be quickly corrected at the chair side.

When multiple restorations or fixed partial dentures are being fabricated, greater segments of the occlusion are being replaced, and there is a need for accuracy. If there has been no loss of the vertical dimension of occlusion and no evidence of occlusal disease or an immediate side-shift, the use of a semiadjustable articulator is warranted. Use of a face-bow transfer further minimizes tooth-hinge axis errors, although some still exist if an arbitrary hinge axis is used as the point of reference. Lateral checkbites (interocclusal records) are used to set the condylar inclination, and adjustment for the Bennett angle is possible. This type of instrument will also provide incisal guidance. While errors still exist in the semiadjustable articulator, it is a definite step upward from the nonadjustable articulator.

The final step in the progression of articulators is the fully adjustable instrument. Coupled with the use of a kinematically located hinge axis and an accurate recording of mandibular movement (either a pantographic tracing or a three-dimensional intraoral recording) a high degree of accuracy can be achieved. The intercondylar distance is fully adjustable; the posterior and superior walls as well as the medial wall of the fossae are adjustable; and immediate side-shift can be accommodated.

The fully adjustable instrument is indicated for extensive treatment in which opposing quadrants are restored, for reconstruction of the entire occlusion, and for patients with a significant side-shift during lateral mandibular movements. Its use is particularly desirable when there is a need to restore lost vertical dimension or when there is evidence of occlusal disease and breakdown.

## **SUMMARY**

There are many types of articulators that can be used for making fixed restorations. While unquestionably the most accurate, the fully adjustable instrument is not feasible or necessary for many forms of simple-occlusal treatment.

The effects of tooth-hinge axis radius, intercondylar distance, and condylar inclination on occlusal morphology have been discussed. Guidelines have been proposed for matching the type of articulator with the extent of treatment anticipated. The use of small, nonadjustable hinge articulators is not recommended.

## **References**

- <sup>1</sup> Dawson, P.E.: Temporomandibular Joint Pain-Dysfunction Problems Can be Solved, *J. Prosthet. Dent.* 29: 100-112, 1973
- <sup>2</sup> Ramfjord, S.P., and Ash, M.M.: Occlusion, ed 2, Philadelphia, 1971, W.B. Saunders Company. P. 118
- <sup>3</sup> Ramfjord, S.P.: Dysfunctional Temporomandibular Joint and Muscle Pain, *J. Prosthet. Dent.* 11: 353-374, 1961.
- 4 Stallard, H., and Stuart, C.E.: Eliminating Tooth Guidance in Natural Dentitions, *J. Prosthet. Dent.* 11: 474-479, 1961
5. Schuyler, D.H.: Factors Contributing to Traumatic Occlusion, *J. Prosthet. Dent.* 11: 708-715, 1961.



- <sup>6</sup> Yuodelis, R.A., and Mann, M.V.: The Prevalence and Possible Role of Nonworking Contacts in Periodontal Disease, *Periodontics* 3: 219-223, 1964
- <sup>7</sup> Whitsett, L.D., Shillingburg, H.T., and Duncanson, M.G.: The Nonworking Interference, *J. Okla. Dent. Assoc.* 65: 5-8, 1974
- <sup>8</sup> D'Amico, A.: Functional Occlusion of the Natural Teeth of Man, *J. Prosthet. Dent.* 11: 899-915, 1961
- <sup>9</sup> D'Amico, A.: Functional Occlusion of the Natural Teeth of Man, *J. Prosthet. Dent.* 11: 899-915, 1961
- <sup>10</sup> D'Amico, A.: Functional Occlusion of the Natural Teeth of Man, *J. Prosthet. Dent.* 11: 899-915, 1961
- <sup>11</sup> D'Amico, A.: Functional Occlusion of the Natural Teeth of Man, *J. Prosthet. Dent.* 11: 899-915, 1961
- <sup>12</sup> Guichet, N.F.: Occlusion, Anaheim, 1970, Denar Corporation. p. 66.
- <sup>13</sup> Stuart, C.E.: Why Dental Restorations Should Have Cusps, *J. South. Calif. Dent. Assoc.* 27: 198-200, 1959
- <sup>14</sup> Weinberg, L.A.: An Evaluation of Basic Articulators and Their Concepts. Part I. Basic Concepts, *J. Prosthet. Dent.* 13: 622-644, 1963
- <sup>15</sup> Hodge, L.C., and Mahan, P.E.: A Study of Mandibular Movement From Centric Occlusion to Maximum Intercuspatation, *J. Prosthet. Dent.* 18: 19-30, 1967

Dr. Hobo  
15-18, 1-Chome Shohtoh  
Shibuya-Ku  
Tokyo 150, Japan

Drs. Shillingburg and Whitsett  
University of Oklahoma  
College of Dentistry  
Oklahoma City, Okla. 73190